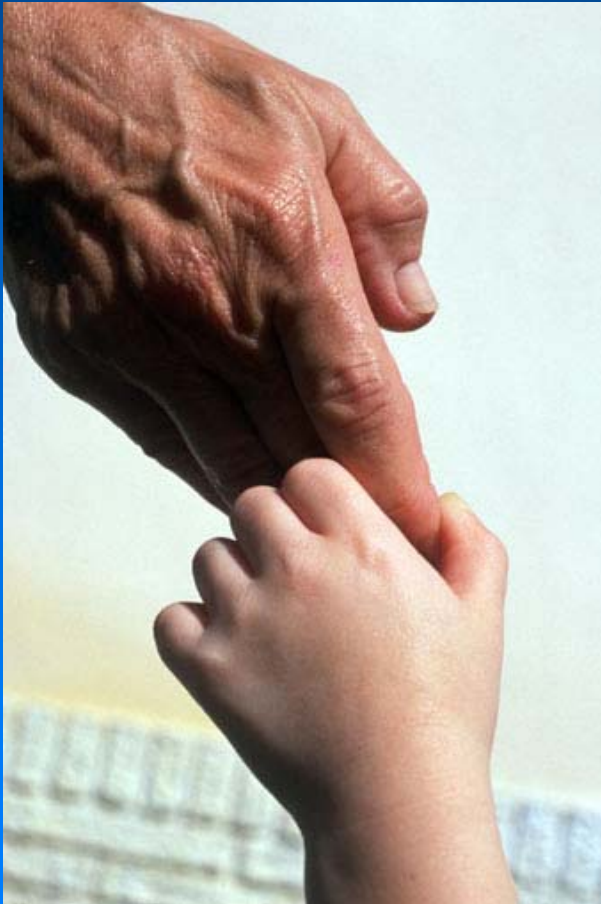

Placenta Pathology

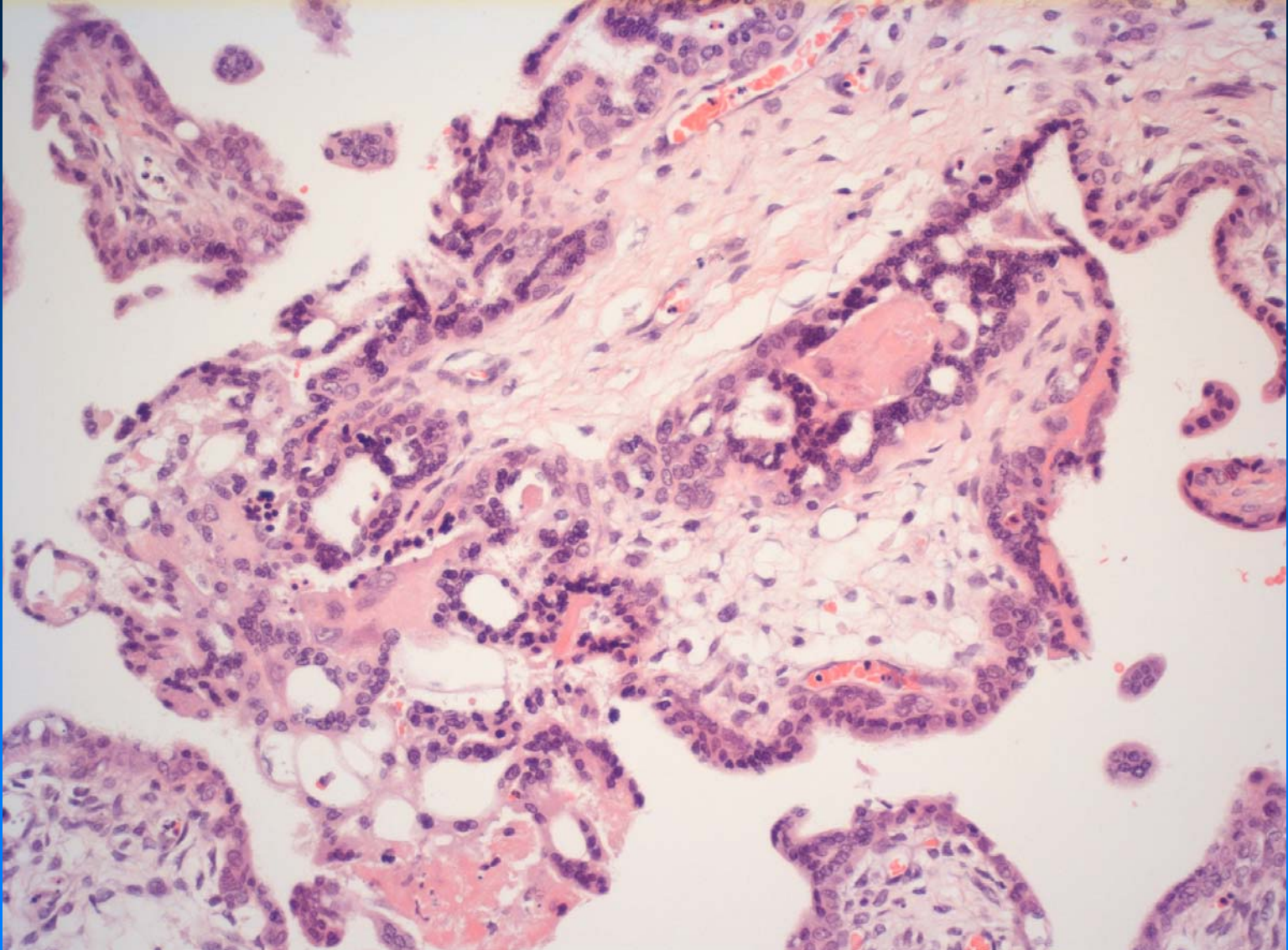
Slide Show (selection only)

Consolato Sergi, MD, PhD (Habil), Hon. Clin. Reader (UK)



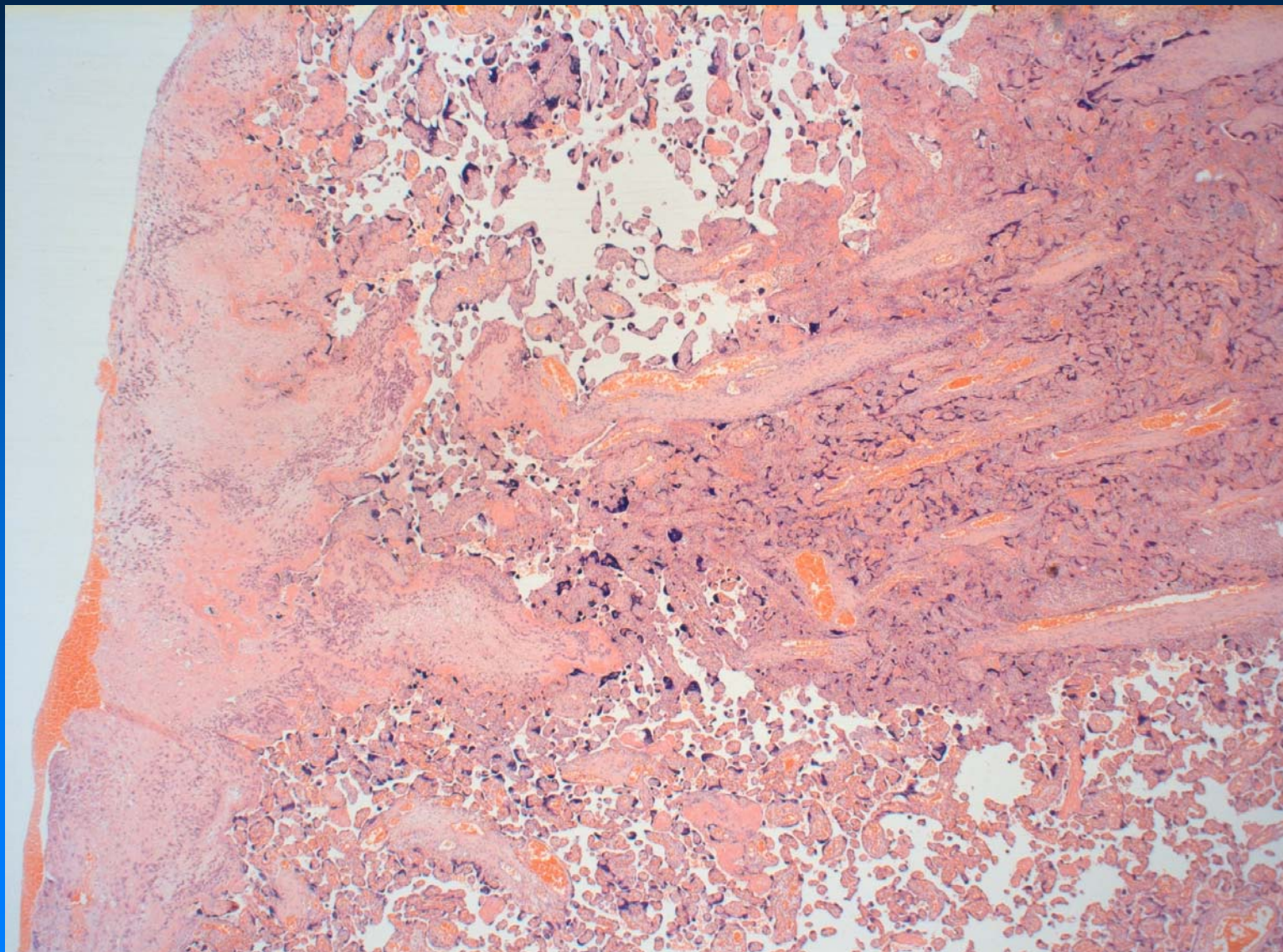
Placenta Pathology

Case 3



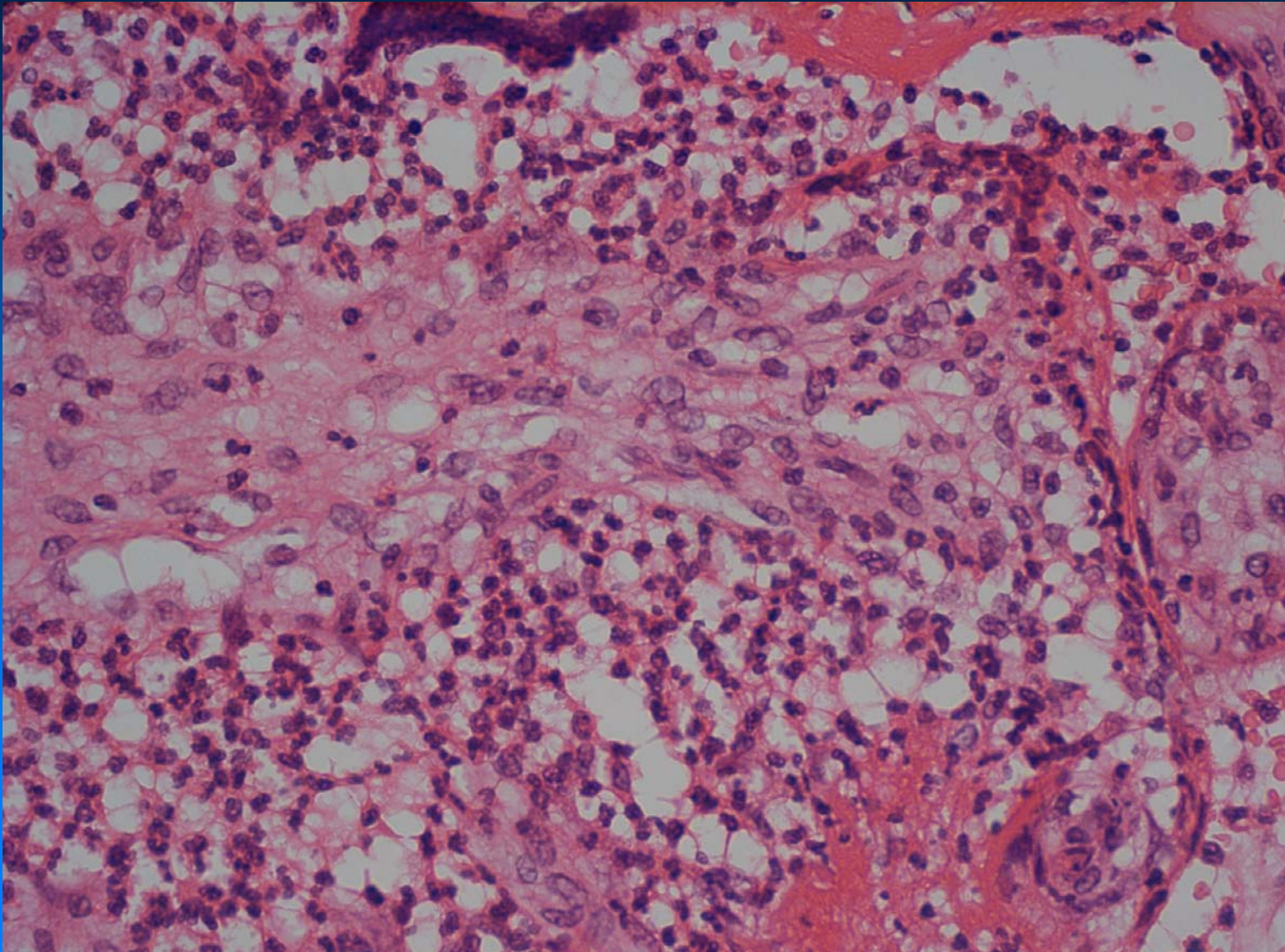
Placenta Pathology

Case 4



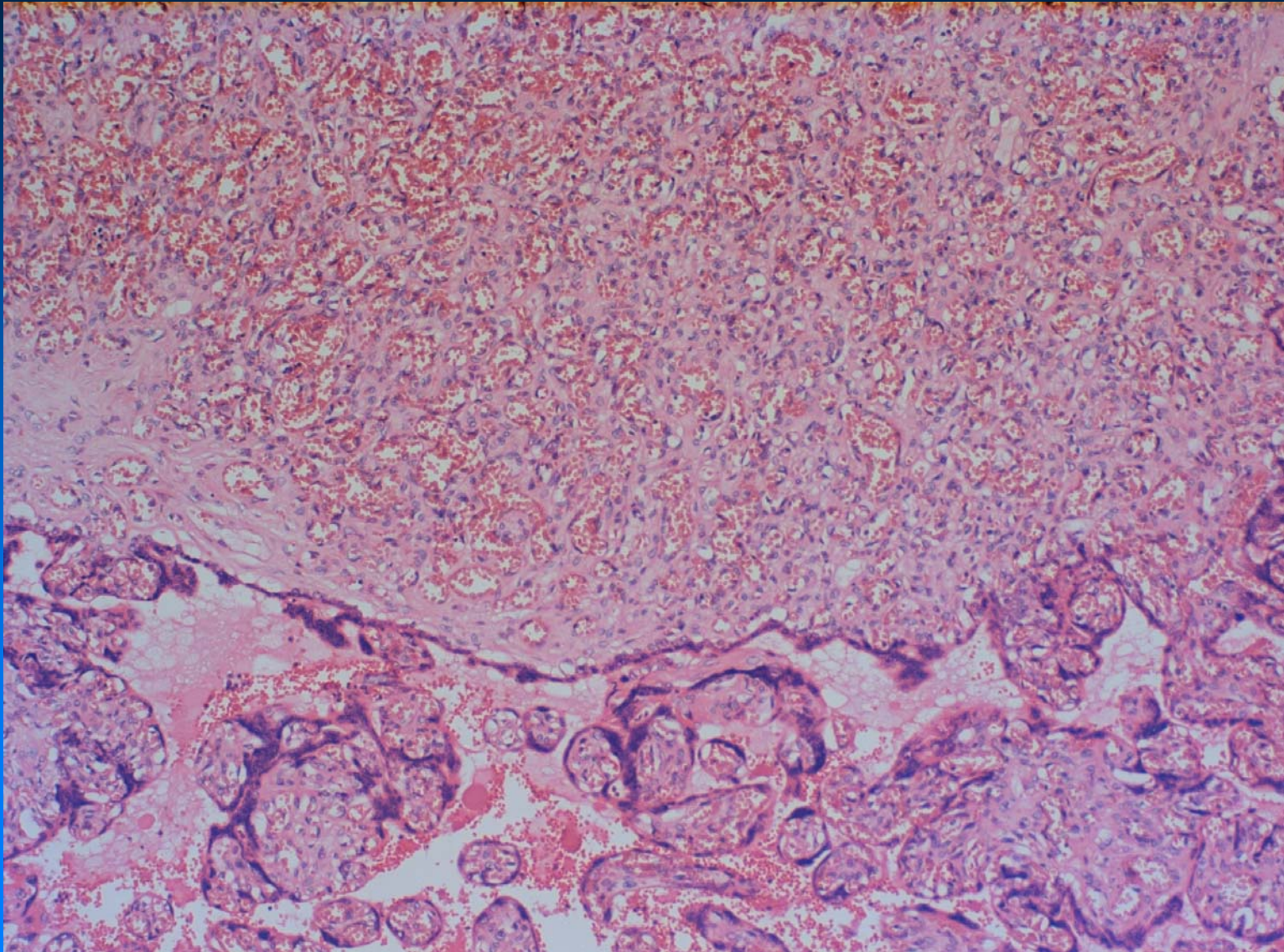
Placenta Pathology

Case 8



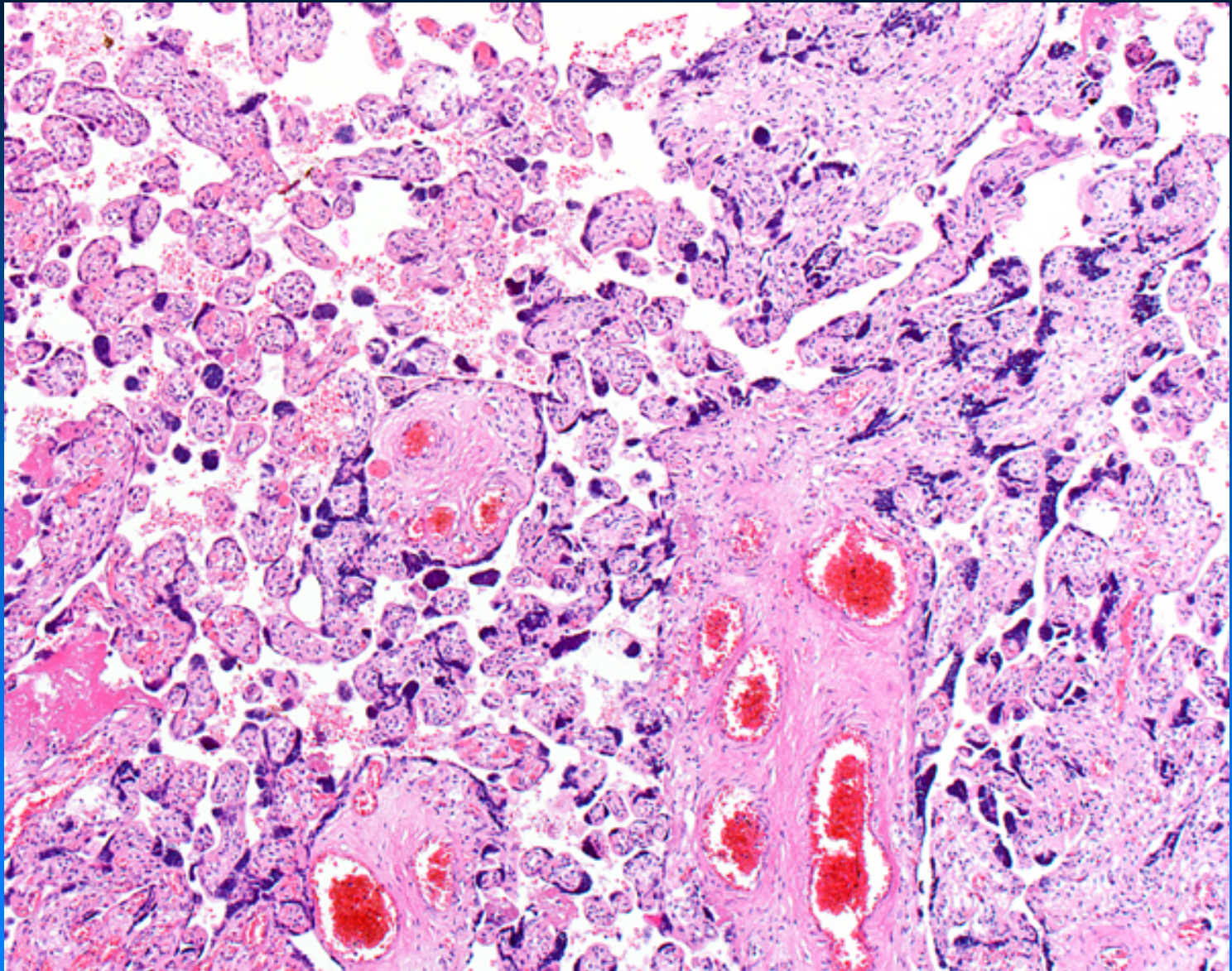
Placenta Pathology

Case 10



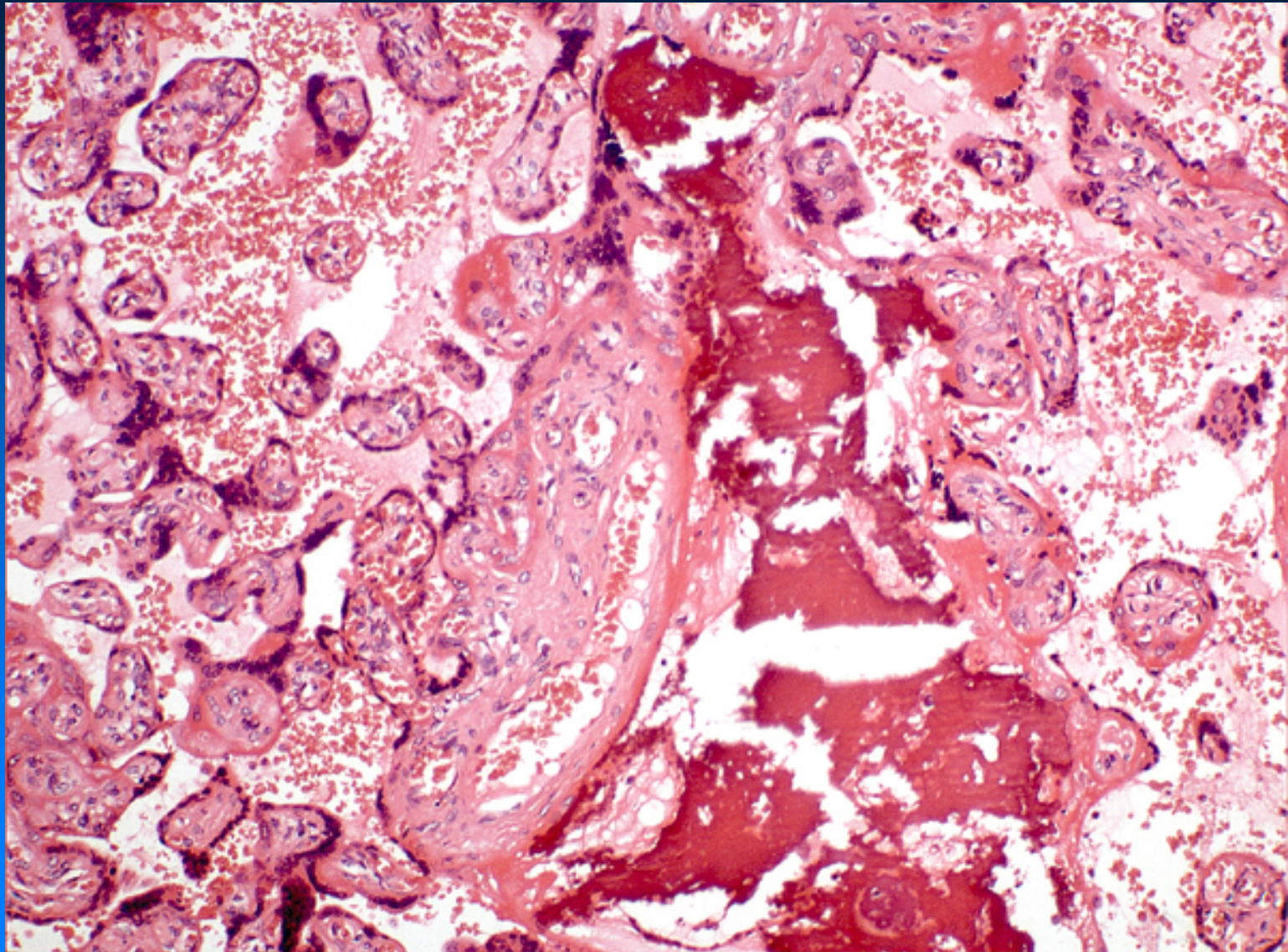
Placenta Pathology

Case 12



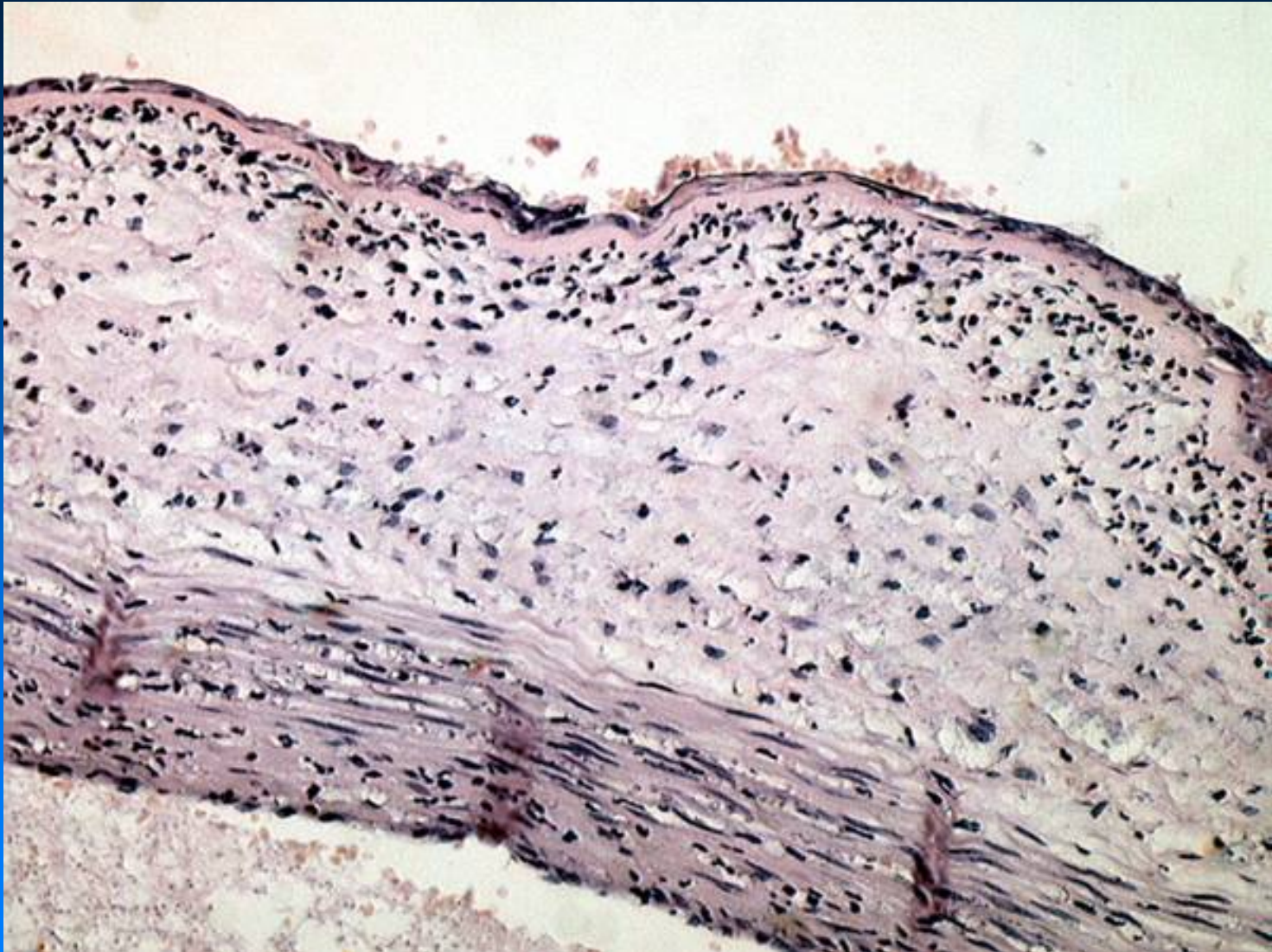
Placenta Pathology

Case 15



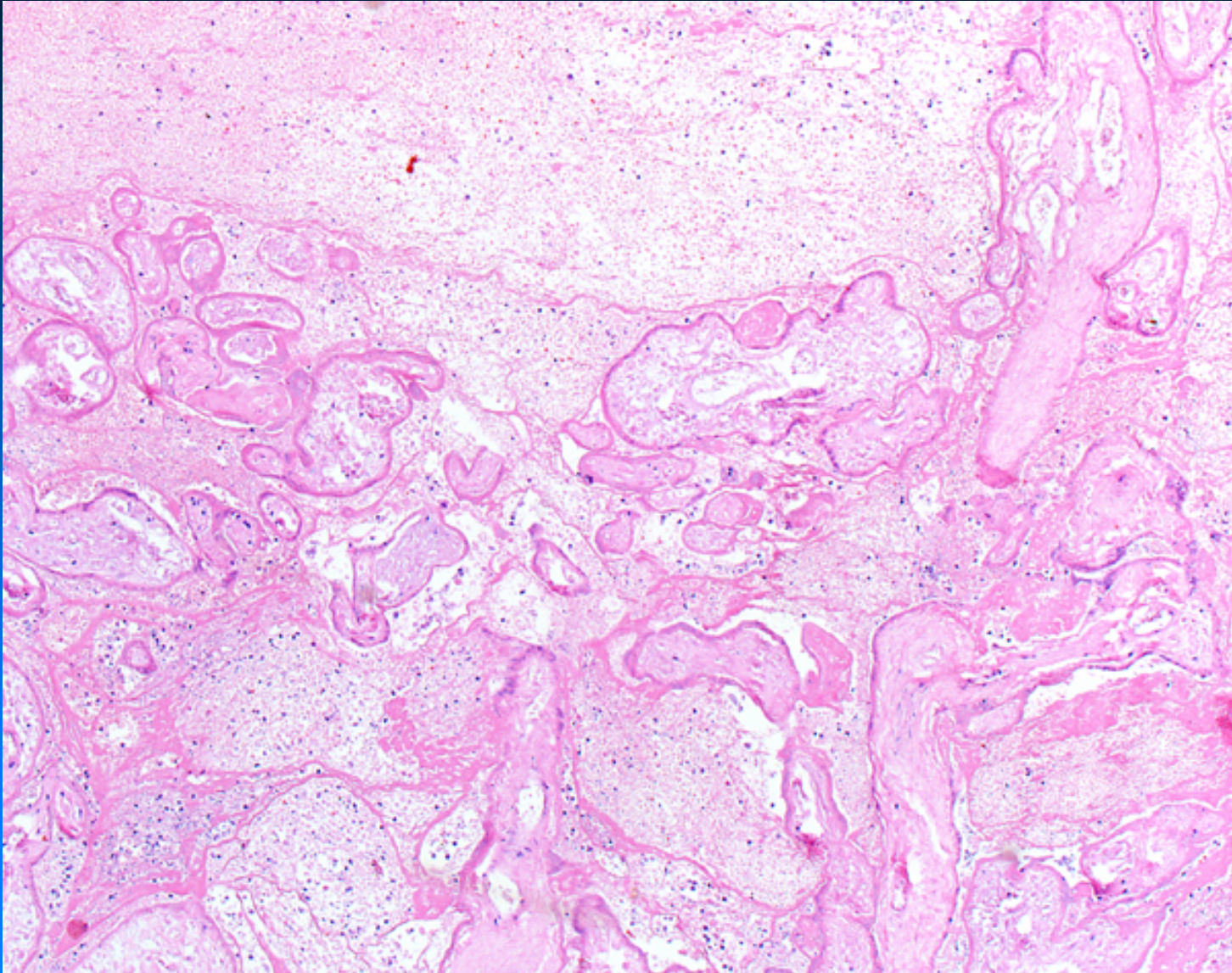
Placenta Pathology

Case 18



Placenta Pathology

Case 24



Placenta Pathology

Case 30

